

Indirect sinus lift with CPS putty

DR. LANKA MAHESH, DR. MANESH LAHORI, DR. SAGRIKA SHUKLA AND DR. PRERNA KAUSHIK

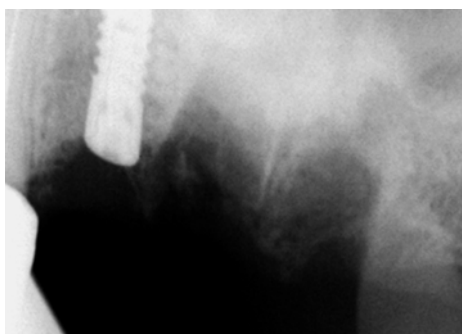

FIG 1: Immediate Implant

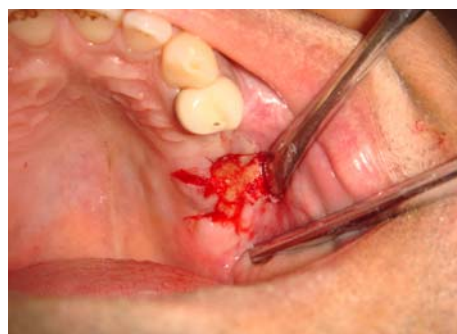

FIG 2: CPS Putty placed

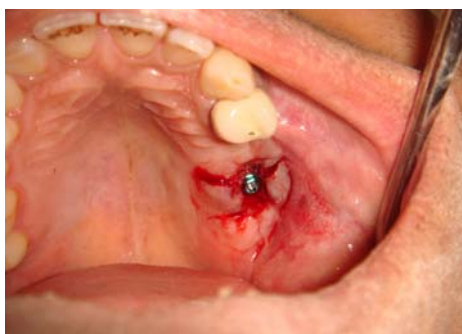

FIG 3: Implant placement in respect to 25

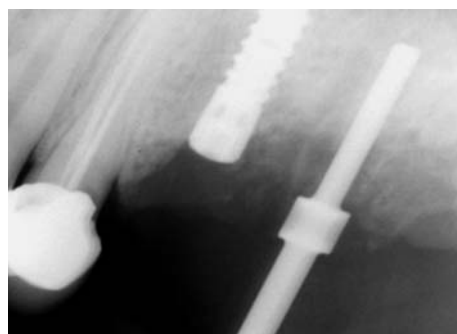


FIG 4: FDI to check the parallelism

INTRODUCTION

The posterior maxilla often presents with problems of implant placement due to poor quality of bone in conjunction with poor volume of bone. After tooth extraction, bone resorption begins and presence of maxillary sinus makes implant placement impossible in highly resorbed posterior maxilla. In situations where lack of bone volume is related to an enlarged maxillary sinus, elevation of the sinus floor has been advocated for implant placement.

There are three procedures used for increasing bone height;

1. Two step antrostomy (lateral approach) or the direct sinus lift procedure
2. One step antrostomy
3. Osteotome technique (crestal approach) or the indirect sinus lift procedure.

Usually 2-step antrostomy is the choice of treatment, however it takes 6-10 months for placement of final prosthesis. In osteotome technique or indirect sinus lift procedure

immediate implant can be placed and it is less invasive.

In the consensus conference held on sinus lift in 1996 Jensen *et al.* recommended adjusting the surgical procedure according to the residual bone height (RBH). When RBH belongs to classes A and B (10mm and 7-9mm, respectively), the lateral sinus lift surgery can be avoided. The osteotome technique introduced by Summers in 1994 is less invasive, less time-consuming and reduces post-operative discomfort to the patient. Recent meta-analysis done showed it to be highly predictable in several short- and long-term surveys.

In osteotomy with indirect sinus lift, the endosteal implant osteotomy is prepared, 1-2 mm shorter of the floor of the antrum. A flat-end or cupped-shape osteotome of the same diameter as the final osteotomy is selected. It is inserted and tapped firmly in 0.5 - 1.0 mm increments beyond the osteotomy until reaching its final vertical position, upto 2 mm

beyond the prepared implant osteotomy.

This surgical approach compresses the bone below the antrum, causing greenstick-type fracture in the antral floor, and slowly elevates the unprepared bone and sinus membrane over the broad based osteotome. If the osteotome cannot proceed to the desired osteotomy depth after tapping then it is removed and the osteotomy is prepared again with rotary drills an additional 1 mm in depth.

The gap present between the implant and the bone is filled with graft materials to provide primary stability to the implant. There are various graft materials used for this purpose, however synthetically derived Alloplast bone graft material - Novabone has shown high degree of bone formation. It is an osteoconductive bio-active graft material which is a pre-mixed composite of bio-active calcium phosphate silica particulate and a synthetic absorbable binder. The bio-active particulate is composed solely of elements that exist nat-

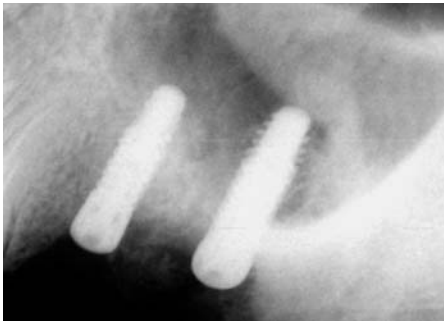


FIG 5: Implant after ISL

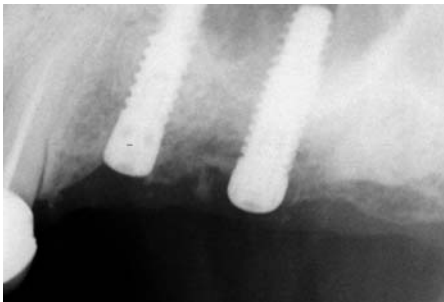


FIG 6: Implants after 6 months

urally in bone such as Ca, P, Na, Si, and O with the binder being a combination of polyethylene glycol and glycerine.

Novabone other than providing an osteoconductive scaffold also functions by a process of osteostimulation. It stimulates osteoblast recruitment, proliferation and differentiation at the defect site and increases rate of bone formation not just at the edges but throughout the defect. It exhibits a higher rate of particle resorption and does not generate bone in non-osseous sites. Results of a study on the effect of silica-containing calcium-phosphate particles on human osteoblasts in vitro demonstrated that this new bioactive glass enhanced the proliferation response of osteoblasts compared with osteoblasts alone and did not induce stimulation of pro-inflammatory markers iNOS and IL-1beta. It also exhibits complete resorption of its particles over a period of time.

CASE REPORT

A 38 years old patient reported to the dental office, with fractured tooth 25 and 26. After discussion of all options the patient decided to go for implant retained restoration as he was not in favour of any removable appliance.

On the day of surgery, extraction was done on tooth 25 and 26. An immediate Bio-Horizons 4x12, external hex implant was placed for 25.

The extraction socket for 26 was allowed to heal as there was a breach in continuity of the alveolar socket. After 4 months, complete healing of the alveolus was noted and due to insufficient bone height between the floor of the sinus and the alveolus, an Indirect Sinus Lift procedure was performed with 1cc of CPS putty (Novabone Putty) by the osteotome technique and a Bio-Horizons 4x12, external hex implant was placed simultaneously.

GLOBAL INSTITUTE
FOR DENTAL EDUCATION

gIDE / UCLA 2011 2012

STARTS NOVEMBER

INDIA

T-1-YEAR MASTER CLINICIAN PROGRAM IN IMPLANT DENTISTRY

Dr. Egon Euvre
Session I
Implant Dentist

Dr. Sascha Jovanovic
Chair & Session II & IV
Periodontist

Dr. Istvan Urban
Session III
Implant Dentist

Dr. Ed McLaren
Faculty Session IV
Prosthodontist

Dr. Henry Takei
Faculty Session IV
Periodontist

Dr. George Perri
Faculty Session I
General Dentist

WATCH VIDEO

REGISTER NOW

Two of the world's most respected education and academic organizations have joined forces to provide an innovative, technology driven program.

CLASSROOM
Personalized
Clinical Training with
small class sizes

HANDS-ON
workshops with porcine
models each session

IPAD 2
containing most of the
mandatory self-study
material on-the-go

UCLA/gIDE
certificate awarded
upon completion of
1 year course

LITERATURE REVIEW
Extensive research compiled
in digital format by
program faculty

LIVE PROCEDURES
Demonstrations by
expert faculty

YOUR CASES
presented to peers and
faculty for discussion
and review

ONLINE LECTURES
provided as part of your
mandatory self-study
material

MEMBERSHIP
1 year access to
200+ Lectures &
50+ Clinical Videos & more

EXCLUSIVE FORUM
for Master Clinician Program
members where students
& faculty stay connected

What our graduates are saying:

"The Master Clinician Program is everything I expected. It has allowed me to implement many implant procedures, both basic and advanced, immediately into my practice."
- Dr. David Azar, New York, New York - North America Master Clinician Program 2009-2010

"The gIDE Master Clinician Program has completely revolutionized the way I approach implant treatment and has raised my confidence in treatment planning. After just two sessions I have performed 10 sinus lifts via a Window and 3 bone grafts from ramus. Thank you, gIDE."
- Dr. Lutfi Ujam, Jonkoping, Sweden - Mediterranean Master Clinician Program 2010-2011

Questions: +1 310.696.9025 info@gidedental.com

ADA CERP Continuing Education
Recognition Program

Dental Practice // July-August 2011 // Vol 10 No 3 **25**

implantology section

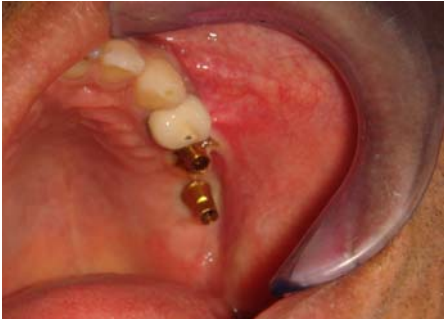

FIG 7: Abutment in respect to 25 and 26

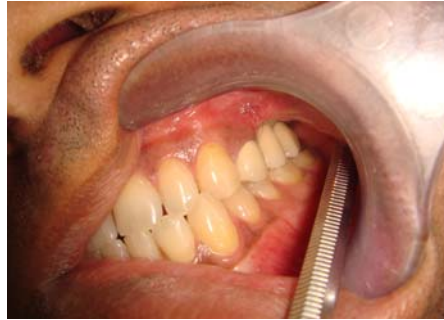

FIG 8: Prosthesis in occlusion

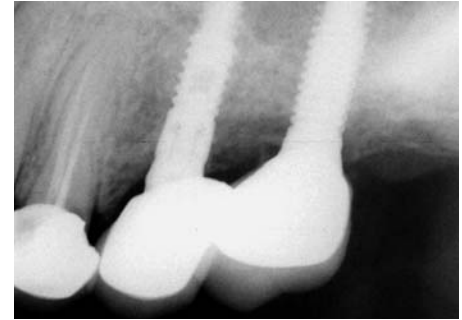


FIG 9: RVG after crown cementation

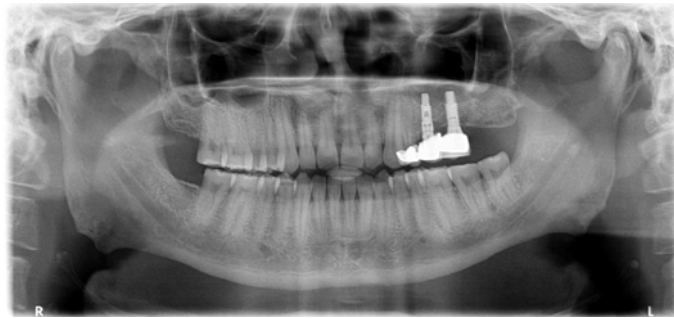


FIG 10: One year post operative OPG showing stable crestal bone and complete graft maturation within the antrum

At 6 months post operative, it was decided to load the implants. Healing collars were placed and the PTV (Periotest Value) was confirmed at -6.8 suggesting successful osseointegration. After 2 weeks an open tray impression was recorded in Affinis Putty (Coltene Whaledent), and a 2 unit splinted PFM prosthesis was cemented using Rely-X U 100 cement (3M Espe).

ous implant placement is sufficient to create bone beyond the natural limit of the sinus. This technique offers the advantage of a more conservative procedure, localized augmentation of sinus, and less postoperative morbidity. This technique can be successfully used for sinus augmentation with immediate implant placement.

For a complete list of references, email info@dental-practice.biz

RESULT

1 year postoperative result shows successful maintenance of osseointegration, stable crestal bone levels and complete graft maturation within the antrum.

CONCLUSION

Elevating the Schneiderian membrane with simultaneous

About the AUTHORS



Dr. Lanka Mahesh is an implantologist practicing in New Delhi. He is a Fellow and Diplomate of International College of Oral Implantologists (USA) and the Indian Society of Oral Implantologists. He has undergone advanced surgical training at USA and Spain. He has also authored "Practical Guide to Implant Dentistry" published by Quintessence. He has lectured extensively in India and abroad and has numerous publications on implant related topics.

Dr. Manesh Lahori is Professor, Department of Prosthodontics, KD Dental College and Hospital, Mathura.

>> POINTS TO PONDER

DR. KUMARSWAMY

Indirect sinus lift with CPS putty



The challenge of creating a BONE BED in deficient sites offers a very narrow range of possibilities in the maxilla posterior areas. The bone type would allow easy manipulation of the Type III bone either through the crest with sequential osteotomes or by way of a lateral window approach. It is very important for the clinician to understand a few factors before embarking upon the crestal osteotomy sinus floor elevation technique.

1. At least 5 to 7 mm of bone should be present (as conveyed through a CT/CBCT) from the floor of the sinus to the bone crest.
2. The use of a saucer shaped osteotome is always preferred to a bullet ended osteotome.
3. The strokes with a mallet on the osteotome should be light, short and

sure to ensure proper direction of the osteotomy.

4. Minimal time to be taken between the last osteotome and the implant placement as in case of very soft bone there could be interference to the implant placement.
5. In case of a rupture of the schneiderian membrane (which is very difficult to detect) the bone graft particles could scatter all over the sinus and also could be snuffed out of the nostrils. This technique is widely getting accepted and there are various ways of elevating the sinus floor including the balloon technique and the disc ended drill technique from Korea.

Dr. A. Kumarswamy completed his Post Graduation in Periodontology in 1982 from GDC, Mumbai. His clinical skills are focused on diagnosis and treatment of any condition related to the soft tissue and the surgical aspects of Implantology. He runs a private practice in Mumbai.